

Podiatry Today

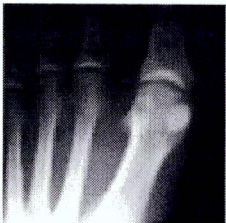Why We Should Consider Arthroscopic Treatment For The Chronically Diseased Sesamoid

Monday, 02/24/14 | 9631 reads

Issue Number: Volume 27 - Issue 3 - March 2014

Author(s): John F. Grady, DPM, FASPS, FACFAOM, and Katy Trotter, DPM

Although hallux valgus and hallux limitus comprise the majority of first ray pathology, sesamoid disorders are not uncommon and may even carry greater morbidity that demands attention. A generic diagnosis of sesamoiditis may encompass several etiologies including fracture, symptomatic nonunion, avascular necrosis, osteoarthritis, dislocation, infection and symptomatic bipartite sesamoids.¹



Upon diagnosis, conservative care begins and includes offloading with accommodative padding, rest and anti-inflammatory medication. Further conservative care for those unresponsive to initial therapies includes steroid injections, below-knee cast/boot immobilization, bone stimulation and radial extracorporeal shockwave therapy.^{1,2}

When isolated sesamoid disease becomes refractory to conservative treatments, physicians face what seems to be a last resort: removal of the painful sesamoid. While this is seemingly a benign procedure, an isolated sesamoidectomy is not without complications. Accordingly, one must weigh the benefits of pain relief against the postoperative complications. Complications may include continued pain, painful scars, wound dehiscence, infection, hallux stiffness, hallux hammertoe, hallux varus, hallux valgus, neuritis, injury to the remaining sesamoid and the inability to resume desired activity.^{1,2}

Saxena and colleagues sought to determine the time to return to activity, particularly in athletically active individuals, when they performed 26 sesamoidectomies in 24 patients.¹ Prior to the surgery, the patients in the study had between three and 48 months of unsuccessful treatment consisting of offloading orthotics, injections, non-steroidal anti-inflammatory drugs and physical therapy. Overall, 20 of 24 patients were able to return to their desired level of activity with no patients developing injury to the remaining sesamoid at an average follow-up of seven years. Complications included two patients with nerve entrapment, two patients with hallux valgus, one patient with hallux varus and one with a loss of hallux flexion, requiring fusion. Patients returned to activity as early as seven weeks. Others have reported the incidence of hallux valgus following tibial sesamoidectomy at 42 percent.³

The sesamoid apparatus has four functions: aiding shock absorption; increasing plantarflexion power at the first metatarsophalangeal joint (MPJ); maintaining an equal and smooth arc of motion of the first MPJ; and protecting the flexor hallucis longus as it courses distally.^{4,7} The sesamoid bones and apparatus inherently serve these valuable functions. The reported complications give credence to this fact and one should attempt to maintain and salvage as much of the apparatus as possible. Physicians, therefore, should not be quick to settle for the less than desirable sesamoid removal and consider a minimally invasive, more technically demanding and less practiced surgical intervention in arthroscopic debridement, drilling and removal of loose fragments to restore and salvage the sesamoid.

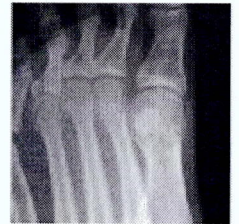Case Study: How Arthroscopic Debridement Can Preserve The Remaining Sesamoid

The following case study highlights not only the fact that isolated sesamoid removal can and often does cause morbidity to the remaining sesamoid, it also demonstrates the drastic and impressive recovery of the remaining sesamoid for which surgeons had heavily contemplated removal.

A 34-year-old female first presented to the office in 2007 for evaluation of a painful tibial sesamoid of her left foot. She had previous removal of the fibular sesamoid and received a diagnosis of avascular necrosis.

Since that time, she developed stiffness and pain that was worse than before the initial surgery. Her physical exam on the first visit was notable for 15 degrees of dorsiflexion and plantarflexion of the first MPJ. The patient demonstrated an antalgic gait, walking with the hallux completely off the ground of the affected foot.

Radiographs at this visit were notable for significant erosion, narrowing and asymmetry of the sesamoid-metatarsal articulation with hypertrophy, sclerosis and erosions present on the tibial sesamoid. An ultrasound scan using an 8 MHz probe demonstrated degeneration within the sesamoid-metatarsal articulation.

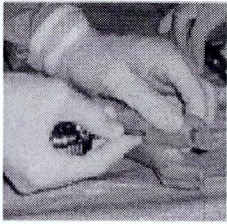


Offloading started at this first visit. There was minimal relief with aggressive offloading and the patient subsequently received steroid injections, a prescription for physical therapy and even visited a pain control specialist over the course of the next six months.

The patient returned in May 2008, continuing to complain of 10/10 pain while standing and ambulating. At this point, atrophy was visible under the sesamoid and we thought the patient might benefit from a sesamoidectomy as no other options existed. However, in order to preserve the remaining sesamoid, we decided to perform arthroscopic debridement of the sesamoid, including osteochondral defects and loose fragments.

We performed the surgery in May 2008. We marked portals using the typical dorsomedial, dorsolateral and straight medial arthroscopy portals of the first MPJ.⁵ Appreciating the anatomy, we took care to avoid branches of the deep peroneal, medial dorsal cutaneous and saphenous nerves. Palpating the joint line helped identify the medial and lateral border of the extensor hallucis longus. We then inserted a 19 gauge spinal needle into the joint and inflated the joint with 5 mL of normal saline. We made skin incisions and bluntly dissected subcutaneous tissue with a hemostat to reach the deep capsule. We inserted an obturator and cannula into the joint followed by a 2.7 mm (one can use 1.9 mm), 30 degree arthroscope. Plantarflexion of the hallux facilitates exposure.

When visualizing the dorsomedial portal, the first metatarsal head is proximal, the tibial sesamoid is central and the proximal phalanx base is visible at the top. In the corresponding arthroscopic view, the tibial sesamoid is to the left and the metatarsal articulation is above. The abnormal cartilaginous defect is visible centrally on the sesamoid and appears walled off as a partial avascular necrosis. The procedure involved removal of the lateral portion of the tibial sesamoid along with debridement of this defect.



From the first postoperative visit forward, the patient had a drastic reduction in pain and no pain on her last visit in September 2008. She had achieved 65 degrees of dorsiflexion and 32 degrees of plantarflexion, and was returning to all desired sporting activities. A subsequent ultrasound of the joint revealed a reduction in fluid within the apparatus and smooth edges of the sesamoid metatarsal articulation with unrestricted motion.

A Closer Look At The Authors' Experience

Between 1988 and 2008, 432 patients (252 female, 180 male) had a diagnosis of sesamoid disorders at the Foot and Ankle Institute of Illinois, excluding acute fracture. The most common diagnosis was sesamoiditis (57 percent), followed by avascular necrosis (13 percent), arthritis (13 percent), non-union fracture (10 percent) and exostoses (7 percent). Of these patients, offloading (accommodative orthoses) was successful in 72 percent of these cases. This is a reminder that most sesamoid disease will respond well without patients entering the operating room.

Of the 122 (28 percent) patients who were non-responsive to conservative care, the majority consisted of those who had avascular necrosis or non-union of a fracture. Offloading was unsuccessful in only 10 to 20 percent of those diagnosed with exostoses, sesamoiditis and arthritis.

Thirty-nine of 122 patients had excision of the affected sesamoid. After six months, only 34 (28 percent) were pain-free and performing desired activity. Twelve patients (31 percent) had continued pain that kept them from performing desired activities. In fact, four of 12 patients had unsuccessful removal of the other sesamoid, requiring arthrodesis in two, a successful metatarsal head resection in one and the other refusing surgery. Two of 12 patients had a successful metatarsal head resection and two patients had an elevating osteotomy, which relieved pain in one patient. The remaining four patients refused surgery.

Four patients had sesamoid planing and after six months, three were pain-free and able to perform desired activity. We performed this treatment specifically for those with exostoses or notably hypertrophic sesamoids.

Two patients had arthrodesis, both of whom were neither pain-free nor able to perform desired activity. Three of 12 patients had joint replacement, which was successful in only one patient. Two patients had metatarsal head resection, which was successful regarding pain and function after six months. After one year, however, one developed second metatarsalgia and had a subsequent resection.

Twenty-nine patients had an elevating osteotomy, which was 31 percent effective in achieving desirable pain and function levels.

Most interesting is that 13 patients had arthroscopy and all but one were pain-free and able to perform desired activities after six months with the one failure carrying the diagnosis of sesamoiditis. We performed these arthroscopic debridements on those with chronic non-unions, exostoses and partial avascular necrosis.

In Conclusion

While clinicians can often relieve sesamoiditis by conservative measures, the condition may remain persistent and cause significant pain and loss of desired activity, especially for those with avascular necrosis and non-unions of one or both sesamoids. The aforementioned case report highlights the fact that sesamoid removal is not without complication. The apparatus and sesamoid no longer function as designed, taking on more weightbearing forces and being subject to altered joint mechanics.⁶

As specialists of the foot and ankle, podiatrists must seek a more refined, proficient way to treat these disorders rather than succumb to the less advanced and destructive removal of the affected bone. Surgeons should attempt to salvage and restore the function of the joint. Arthroscopy offers the unique advantage of

accomplishing these goals. We encourage the foot and ankle surgeon to consider this in his or her armamentarium for an often disabling disease.

Dr. Grady is the Director of The Foot and Ankle Institute of Illinois. He is the Chief of the Podiatry Section of the Jesse Brown Veterans Affairs Medical Center and the Director of the Podiatric Surgical Residency Program at the Westside Division of the Veterans Administration Chicago Healthcare System. He is board-certified by the American Board of Podiatric Surgery, the American Board of Podiatric Medicine and the American Board of Wound Management. Dr. Grady is a Fellow of the American Society of Podiatric Surgeons and is the Scientific Chairman of the Midwest Podiatry Conference.

Dr. Trotter is a second-year resident at the Jesse Brown Veterans Affairs Medical Center. in Chicago.

References

1. Saxena A, Krisdakumtorn T. Return to activity after sesamoidectomy in athletically active individuals. *Foot Ankle Int.* 2003; 24(5):415-9.
2. Bichara DA, Henn RF, Theodore GH, Sesamoidectomy for hallux sesamoid fractures. *Foot Ankle Int.* 2012; 33(9):704-06.
3. Nayfa TM, Sorto LA. The incidence of hallux abductus following tibial sesamoidectomy. *J Am Podiatry Assoc.* 1982; 72(12):617-20.
4. Garrido IM, Bosch MN, Gonzalez MS, Carsi VV. Review: Osteochondritis of the hallux sesamoid bones. *Foot Ankle Surg.* 2008; 14(4):175-179.
5. Chow JCY. Arthroscopy of the great toe. In *Advanced Arthroscopy*, Springer Verlag, NY, 2001, pp.675-84..
6. Lee S, James WC, Cohen B, Daves WH, Anderson RB. Evaluation of hallux alignment and functional outcome after isolated tibial sesamoidectomy. *Foot Ankle Int.* 2005; 26(10):802-809.
7. Richardson EG. Injuries to the hallucal sesamoids in the athlete. *Foot Ankle Int.* 1987; 7(4):230.

5

0

0

googleplus

1

Add new comment

Your name

E-mail

Homepage

Comment *